

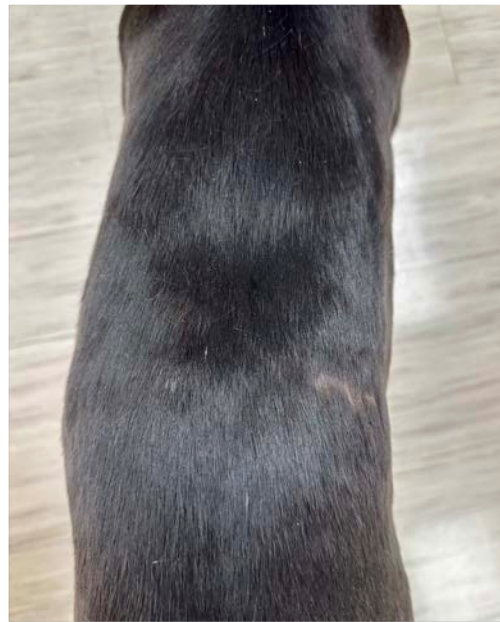

PAWSITIVE PRESS

Caring for Pets with Love & Kindness Since 1977



Trenton Today



The Case of Trenton & the Butterfly

BY CHRISTEN WOODLEY, DVM

Sweet Trenton came to me early one morning almost a year ago. Stoic and sleek and calm as if nothing was wrong. A brave young greyhound, seemingly unaware to the large, open laceration spanning across the entire saddle of her back. Trenton had gone outside for her morning routine, and best guess is she somehow slinked underneath a yard butterfly sculpture at just the right angle so as to cause a large open laceration (*photos inside*). Thankfully there was no active bleeding and she was stable and calm and unaware of her injury. My dear greyhound! Lacerations, especially larger ones, are traumatizing. And understandably scary because none of us wants to see our pet injured or in pain. Laceration wounds can also be daunting because there are a multitude of factors that play into the healing process and it often can take longer than you would expect...*Continued on page 2...*

1

FEATURED

Trenton & the Butterfly

2

MEET LOBBEN

Retired Sled Dog

3

FEB. COUPONS

- > \$40 off Labwork
- > \$5 Nail Trim

Bringing your pet in for a nail trim?

Pick up your *Petiture club* punch card and when you buy 9 nail trims the 10th one is free!

Tell your friends and family...



In addition to seeing your adorable cats and dogs, Dr. Sandra and Dr. Fazio are seeing your exotic pets too! Call now to schedule appointments for:

- Guinea Pigs
- Hedgehogs
- Ferrets
- Hamsters
- Rats
- Mice
- Gerbils
- Tortoises
- Turtles
- Bearded Dragons
- Non-Venomous Snakes

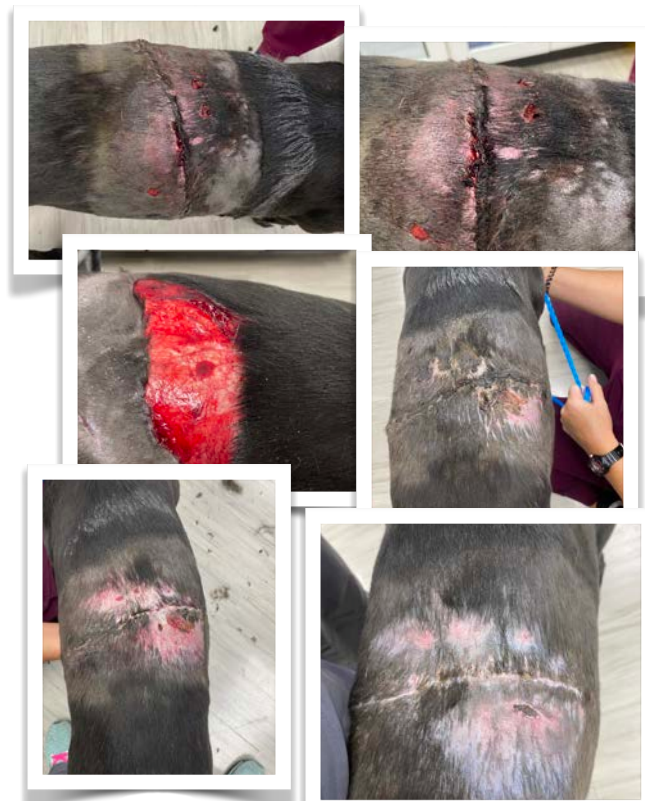Visit ahofd.com for a full list of our services for exotic pets.

...Trenton & the Butterfly

The obvious early concerns are making sure the pet is stable, controlling any bleeding, and trying to get in front of decontamination and infection. What doesn't meet the eye acutely is how extensive the trauma to the tissues might be. Wounds take time to declare themselves. Meaning the wound health and size we see with our naked eye at the time of the injury may be very different than what becomes apparent over the next days to weeks. These wounds can often have tension due to location and size/amount of tissue we have to work with when attempting closure, etc. Skin tissue is very delicate and there are areas that may die, areas we may need to trim or freshen, areas that may develop inflammation and swelling or pocketing, etc. For these reasons many wounds become larger and more open days after the injury, before they can be safely closed and healthy tissue can be laid down in the healing process.

Trenton was a model citizen during the weeks-long process of wound care. We used a combination of antibiotics, pain medication, calming medication, cold laser, sutures, bandaging, and some eastern medicine modalities to help with clotting/seeping and for help in drying out and infection control of the wound. A large obstacle we have to consider in these types of wounds is movement. Trenton is a star pupil and if we could talk to pets and have them understand they need to be a couch potato for their own good that would be amazing. But in pets we do often need to use medication to aid in helping to keep them calm and limit activity, as movement is our enemy in wound healing and will make the process longer and more grueling with a higher rate of complications. Movement can exacerbate pulling of the wound/suture line, cause fluid to build up, cause swelling, lead to dehiscence, etc. Bandaging helps to protect the area and can also create a light pressure so as to help reduce swelling. But it also comes with a set of risks. When repeated changing of bandaging is needed over time, it can cause hair thinning, soreness/rawness to the skin, and in worse case scenarios can apply too much or unwanted pressure and become more of a tourniquet. Something we never want!

Trenton's case was unique in that, though her wound displayed no active bleeding on presentation or during debridement, hours later she began to have seeping issues and bleeding causing bruising and swelling. All of her routine clotting profiles and factors were within normal limits. What she displayed that I had never seen and therefore what she taught me, was that greyhounds in particular can have something called accelerated fibrinolysis, or fibrinolytic syndrome. Which essentially is a cascade that



Trenton during the month of her injury.

can come about when there is acute trauma and inflammation to tissues. These patients make the necessary materials to form clots, but then their body breaks the clot down too quickly, causing unforeseen delayed bleeding typically within hours of a trauma, or surgery, etc. It can be extremely difficult to test for and diagnose, and can range in severity from increased bruising to life threatening hemorrhaging. This condition is most common in greyhounds, though does not affect all of them and we cannot know which ones will be affected. Sometimes these patients have even had prior surgeries and done fine yet now show symptoms. So in Trenton's case specifically we added in a drug called aminocaproic acid to help stabilize the clots by reducing their breakdown.

Trenton's case required numerous visits over a period of weeks for evaluation, bandage changing, laser therapy, medication adjustments, etc. I am happy to say that one month later she was finally healed with healthy tissue closure and happy to go back about her regular activities, just no butterfly garden for her! And one year out she barely has a scar. Thank you so much to Julie Bryan and Lisa and Jimmy Dail for your patience and willingness to let us be a part of care team Trenton.


Meet Lobben

RETIRED CHAMPION SLED DOG & NEW AHOD PATIENT :)

Sled dog litters are very commonly named after a theme. Lobben's litter's theme is boots. A Lobben is a Norwegian felted boot that many mushers wear. Sorrel, his sister, is named after the super cute sorrel snow boot. Steiger, his brother, is named after Steiger Mukluk –also very common northern mushing footwear. Danner, his other brother, is named after the hiking boot. All four of them are happily retired in Alaska. Lobben is the only snowbird of the group!

Lobben's dad, Diesel, was also an accomplished and champion sled dog. Lobben officially retired when he was 10 years old, in May 2022. His last few working years were spent training young lead dogs and taking people on small dogsled tours.

Now that he's retired, Lobben enjoys sunbathing and playing fetch on the beach. He is the buddha incarnate and loves all beings, big and small.



Lobben (with Alex)



FEBRUARY COUPONS

Present these coupons during any qualified appointment scheduled during the month of February!



\$ 5.00
NAIL TRIM WITH ANNUAL EXAM

Call for an appointment today 727-733-9351

This coupon is good for one \$5 nail trim (\$29 value) during your cat or dog's annual exam appointment. May not be combined with any other coupons or discounts. Must be presented at the time of purchase.

EXPIRES 2/29/24



\$40 Off
PRE-DENTAL LABWORK
When scheduling a dental the same day

Call for your appointment today 727-733-9351

Dental must be scheduled during or before labwork visit. May not be combined with any other coupons or discounts. Coupon must be presented at the time of service.

EXPIRES 2/29/24